

# Problem Solving

## Common Problems

The most common problems your child may experience when you are home are:<sup>2</sup>

- ▶ Irritated and red skin
- ▶ Barrier not sticking/leakage
- ▶ Dehydration
- ▶ No output from the stoma
- ▶ Stoma issues (bleeding, prolapse, retraction)
- ▶ Medical emergencies
- ▶ Long-term problems

Let's talk about each one of these so that you can know what to watch for, what you can do, and when to reach out for help.<sup>2,3</sup>



### WATCH VIDEO

Ostomy Home Skills  
Program: Problem Solving



## Irritated and Red Skin

The skin around your child's stoma can become irritated and red. This is the most common problem for children with a new ostomy. It is most often due to stool on the skin, or from tape and barriers pulling off the top layer of skin.

### WHAT YOU CAN DO

Check the skin with each pouch change. Red skin can be due to a poor fit of the skin barrier (wrong size or shape).

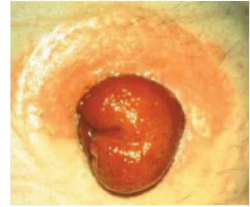
- ▶ Measure the stoma and cut the barrier to fit the stoma skin junction. The stoma size will change during the first several months after surgery.
- ▶ Do not wear the skin barrier too long. Suggested wear time is 3 to 5 days. Wear time can depend on how often the pouch is emptied, the amount of sweat, level of activity and body shape.
- ▶ If the skin is irritated or weepy (wet), apply skin barrier powder.
- ▶ If there is seepage of stool under the stoma barrier, or by a skin fold, you may need a moldable ring to fill in any gaps or a convex pouch.
- ▶ Don't delay in asking for help. One visit with an ostomy nurse could save you from going through extensive trial and error.

## RECOGNIZING COMMON SKIN PROBLEMS

It can be hard to recognize why you are having skin problems. Here are some common problems and what you can do first. If there is no improvement in a few days—get help. Call your ostomy nurse or other health care provider.<sup>4</sup>

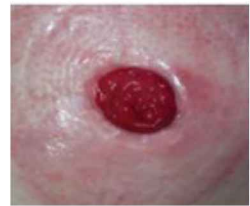### Skin redness directly above the stoma site

This might happen because the barrier is not cut to the correct size. If the skin is weepy, apply stoma powder, resize the barrier, and apply to the stoma. The site should look better with the next pouch change.



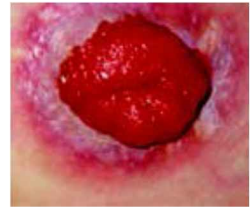### Irritated and red skin around the entire stoma site

This may happen because the skin is sensitive, or the top layer of skin is being stripped away when you remove the barrier. Be gentle when removing the barrier. You can also use an adhesive remover or try a different barrier.



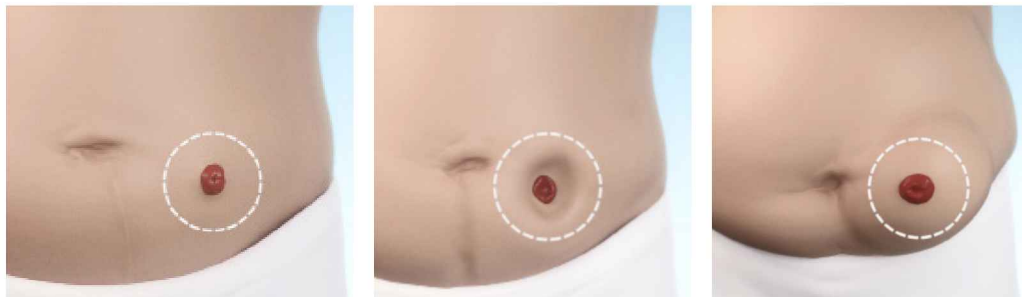### Fungal skin infection

This occurs most often in damp sites, such as in skin folds or under an ostomy barrier. The rash starts as red raised bumps and then becomes more red, sometimes with a white coating. Itching and burning are common. Check the barrier and keep the skin dry. Contact your ostomy nurse or doctor for an antifungal powder.



## Leakage under the Barrier

The shape and position of the stoma determines which barrier your child will need. The abdomen shape around the stoma may be flat, sink in, or extend outward. The stoma itself may be protruding above the skin, at level with the skin or below the skin. Your ostomy nurse can help you with the correct fit.



Flat stoma

Inward stoma

Outward stoma

Images © Coloplast Corp.

### WHAT YOU CAN DO

If the barrier is not sticking, you may want to try:

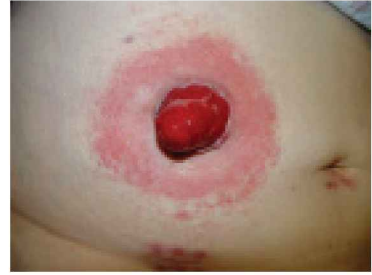- ▶ Remeasure the stoma to be sure that you are using the correct size in the skin barrier.
- ▶ Check the skin around your child's stoma while they are in a sitting position to see if there are any creases or dips around the stoma. If the skin is creased, the stool may be able to lift the skin barrier and damage the peristomal skin. This may mean that you need to use a convex pouching system. Contact your ostomy nurse for suggestions.
- ▶ Clean the skin with water. If you use soap or any adhesive removal wipes, rinse the area well with water to make sure there is no residue left on the skin.
- ▶ Make sure your child's skin is totally dry.
- ▶ Warm the barrier before putting it in place. Some patients find using a hair dryer on low for a few seconds may help.
- ▶ Try a support belt or empty your child's pouch more often. This will decrease the weight and pull on the barrier.

**If you are having trouble getting your barrier to stick or you are using 2 to 3 barriers daily because of leakage, contact your doctor or ostomy nurse for additional help.**

---

## SIGNS OF INFECTION

Redness around the edges of the stoma while it is healing is normal. Call your doctor or nurse for signs of infection around the stoma or wound site. Signs include:



- ▶ Redness, tenderness, and pain that extends 1/2 inch around the incision or stoma, or white/beige fluid draining in the area.
- ▶ Redness, itchiness, and small dots under your child's barrier without any signs of leakage—these may mean your child has a fungal infection.

## Liquid Stool and Dehydration

Dehydration occurs when your body loses more fluid than it takes in. If your child has high volumes of output (diarrhea) from their ostomy or are vomiting, he or she may be at risk for dehydration. Dehydration is the most common reason patients with an ileostomy return to the hospital.

---

## WHAT YOU CAN DO

### Prevent dehydration

- ▶ Have your child drink at least 8 four-ounce glasses of fluid each day. For infants, your medical team will tell you how many bottles each day. This increases as your child grows.
- ▶ Minimize food or drinks that are high in sugar.
- ▶ Keep track of how many times you have to empty your child's pouch in 24 hours. If you are emptying your pouch when it is 1/2 full more than 8 times per day, you need to start replacement fluids.
- ▶ Watch for signs of dehydration. These include:
  - Being thirsty
  - A dry mouth
  - Decreased urine output and or dark urine
  - Dizziness when standing up
  - Muscle or abdominal cramps

## Manage dehydration

- ▶ **Call your doctor or nurse. They will guide you on how much and what type of oral solution your child should drink.** They may prescribe medication that can slow down the intestine. Let your health professional know if your child is losing weight and how often/how much they are urinating.
- ▶ Drink replacement fluids, such as broth, an oral electrolyte drink (Pedialyte®, Rehydralyte®, or Ceralyte®), or a low-sugar drink (Gatorade® or Powerade®).
  - If your child drinks regular Gatorade, dilute it with equal parts water and add in a teaspoon of salt.
  - You can also drink apple or cranberry juice diluted with 3 cups of water and a teaspoon of salt.
- ▶ Eat foods that help thicken stool: whole-grain pasta, rice, potatoes, applesauce, bananas, tapioca, creamy peanut butter, bread, and yogurt.

## Reduced Output from the Stoma

Your child's ostomy is usually active. If your child has a 4- to 6-hour period without stool from an ileostomy, and he or she has cramps or nausea, your child may have an obstruction. There may be blockage from food or adhesions (internal scar tissue).

---

### WHAT YOU CAN DO

- ▶ Encourage your child to chew foods well, especially high-fiber foods such as whole corn, raw vegetables, celery, coleslaw, skins, and seeds. You may see these appear in the pouch undigested.
- ▶ If you think the blockage might be due to food, gently massage your child's abdomen right around the stoma site. This may help increase pressure and help the food blockage to come out.
- ▶ Call your child's surgeon or ostomy nurse or go to your local emergency department if your child continues to have blockage or starts to vomit.

## Stoma Bleeding

You may see a spot of blood on your child's stoma, especially when cleaning or changing the pouch. The stoma has a good blood supply and no longer has the protection of your child's skin, so a spot of blood is normal.

---

### WHAT YOU CAN DO

- ▶ Make sure the bleeding has stopped after a pouch change. The bleeding should stop within a few minutes.
- ▶ You can use a moist cloth and apply mild pressure for a minute.

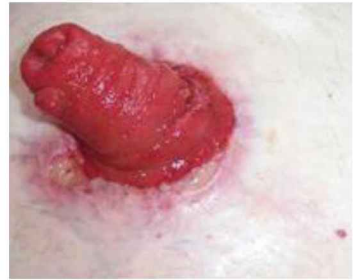## Stoma Prolapse

Stoma prolapse means the stoma becomes longer and sticks out (protrudes) higher above the surrounding skin.

---

### WHAT YOU CAN DO

- ▶ As long as the stoma remains red and stays moist, this is not a medical emergency.
- ▶ Contact your surgeon or nurse and let them know this has happened. Let them know if you need help with applying your pouch.



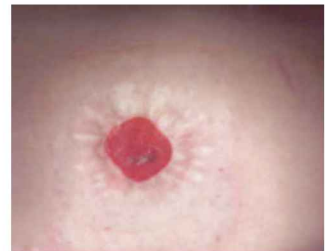## Stoma Retraction

Stoma retraction means the stoma is at or below the skin level. It looks like it is shrinking.

---

### WHAT YOU CAN DO

- ▶ As long as the stoma continues to put out stool, this is not a medical emergency.
- ▶ Contact your surgeon or ostomy nurse to let them know this has happened. Stoma retraction may make it difficult to keep a good seal on the pouching system. Your medical team will help you adjust your child's pouch system so you have a good seal.



SAMPLE

## Parastomal Hernia

A parastomal hernia is a bulge in the muscle around the stoma site. The hernia develops over time and can increase in size. The hernia can become uncomfortable.

---

### WHAT YOU CAN DO

- ▶ Tell your surgeon or ostomy nurse if you notice a bulge in the muscle around the stoma. The pouch system may have to change to keep a good seal around the stoma. A parastomal hernia is repaired surgically.

## Medical Emergencies

Contact your surgeon or nurse immediately or go to the nearest emergency room if there is:

- ▶ A deep cut in the stoma.
- ▶ A severe change in the color of the stoma from bright red to dark, purplish red. A change in color could mean that there's not enough blood being supplied to the stoma. It is unlikely that this issue will happen after your child is discharged from the hospital.
- ▶ A large amount of continuous bleeding (more than 4 tablespoons) into the pouch.
- ▶ Continuous nausea and vomiting.
- ▶ Repeatedly finding blood in the pouch, or bleeding between the edge of the stoma and skin.
- ▶ Continuous diarrhea with signs of dehydration.
- ▶ Severe cramping and no output from the stoma for a period of 4 to 6 hours.

# Additional Ostomy Resources

## Resources

### American College of Surgeons

#### Surgical Patient Education Program

[facs.org/ostomy](https://facs.org/ostomy) | 1-800-621-4111

### Wound, Ostomy and Continence Nurses Society (WOCN®)

[wocn.org](https://wocn.org) | 1-888-224-9626

### United Ostomy Associations of America (UOAA)

[ostomy.org](https://ostomy.org) | 1-800-826-0826

### American Society of Colon and Rectal Surgeons (ASCRS)

[fascrs.org](https://fascrs.org)

### American Pediatric Surgical Association (APSA)

[apsaped surg.org](https://apsaped surg.org)

### American Pediatric Surgical Nurses Association (APSNA)

[apsna.org](https://apsna.org)

## References

1. Bischoff, A, Pena A. Stomas for Large and Small Bowel in P Puri & ME Hollwarth Pediatric Surgery. Eds. 2nd ed. Springer, Berlin Germany, 2019
2. Schaffner, A. Pediatric ostomy surgery. *J Wound Ostomy Continence Nurs.* 2010.37(5):546-8. doi:10.1097/WON.0b013e3181eded6f.
3. Steinhagen E, Colwell J, Cannon L. Intestinal Stomas—Postoperative Stoma Care and Peristomal Skin Complications. *Clin Colon Rectal Surg.* 2017 Jul; 30(3): 184–192. doi: 10.1055/s-0037-1598159. Epub 2017 May 22.
4. Freedman S, Wilan A, Boutis K, et al. Effect of Dilute Apple Juice and Preferred Fluids vs Electrolyte Maintenance Solution on Treatment Failure Among Children With Mild Gastroenteritis: A Randomized Clinical Trial. *JAMA.* 2016 May 10;315(18):1966-1974. doi: 10.1001/jama.2016.5352.
5. Baker ML, Williams RN, Nightingale JM. Causes and Management of a High Output Stoma. *Colorectal Disease.* 2011 Feb;13(2):191-197. doi: 10.1111/j.1463-1318.2009.02107.x.
6. FDA, Imodium Drug Label. RX [https://www.accessdata.fda.gov/drugsatfda\\_docs/label/2005/017694s050lbl.pdf](https://www.accessdata.fda.gov/drugsatfda_docs/label/2005/017694s050lbl.pdf)
7. WOCN, Pediatric Ostomy Care. Best Practice for Clinicians. [https://cdn.ymaws.com/member.wocn.org/resource/resmgr/document\\_library/PEDIATRIC\\_OSTOMY\\_CARE-\\_BEST\\_.pdf](https://cdn.ymaws.com/member.wocn.org/resource/resmgr/document_library/PEDIATRIC_OSTOMY_CARE-_BEST_.pdf)

SAMPLE

---

## ACS SURGICAL PATIENT EDUCATION PROGRAM

### **Director:**

Ajit K. Sachdeva, MD, FACS, FRCSC, FSACME

### **Assistant Director:**

Kathleen Heneghan, PhD, MSN, RN, FAACE

### **Senior Manager:**

Katie Maruyama, MSN, RN

### **Senior Administrator:**

Mandy Bruggeman

---

## PATIENT EDUCATION COMMITTEE

Ajit K. Sachdeva, MD, FACS, FRCSC, FSACME

Lenworth Jacobs, MD, FACS

Jessica R. Burgess, MD, FACS

David Tom Cooke, MD, FACS

Jeffrey Farma, MD, FACS

Nancy L. Gantt, MD, FACS

Lisa J. Gould, MD, PhD, FACS

Alden M. Maier, MD, FACS, FACCP

Karthik Rajasekaran, MD, FACS

Richard J. Shemin, MD, FACS

John H. Stewart IV, MD, MBA, FACS

Cynthia L. Talley, MD, FACS

Steven D. Wexner, MD, PhD(Hon),  
FACS, FRCSEng, FRCSEd, FRCSI (Hon),  
FRCSGlasg (Hon)

---

## OSTOMY TASK FORCE

### **H. Randolph Bailey, MD, FACS**

Colon and Rectal Surgery  
The Methodist Hospital  
Houston, TX

### **Teri Coha, APN, CWOCN**

Pediatric Surgery  
Ann and Robert H. Lurie Children's Hospital  
of Chicago  
Chicago, IL

### **Janice C. Colwell, RN, MS, CWOCN, FAAN**

Ostomy Care Services  
University of Chicago Medicine  
Chicago, IL

### **Martin L. Dresner, MD, FACS**

Chief, Department of Urology  
Southern Arizona VA Healthcare System  
Tucson, AZ

### **John Easley**

Patient Advocate  
Ostomy Support Group of DuPage County  
Clarendon Hills, IL

### **Kathleen G. Lawrence, MSN, RN, CWOCN**

Wound, Ostomy and Continence Nurses  
Society (WOCN®)  
Mt. Laurel, NJ

### **Ann Lowry, MD, FACS**

Colon and Rectal Surgery  
Fairview Southdale Hospital  
Minneapolis, MN

### **Jack McAninch, MD, FACS, FRCS**

Department of Urology  
San Francisco General Hospital  
San Francisco, CA

### **Mike McGee, MD, FACS**

Colon and Rectal Surgery  
Michigan Medicine/ University  
of Michigan  
Ann Arbor, MI

### **Marletta Reynolds, MD, FACS**

Pediatric Surgery  
Ann and Robert H. Lurie Children's  
Hospital of Chicago  
Chicago, IL

### **David Rudzin**

United Ostomy Associations of America,  
Inc.  
Northfield, MN

### **Nicolette Zuecca, MPA, CAE**

Wound, Ostomy and Continence Nurses  
Society (WOCN®)  
Mt. Laurel, NJ